



Emergency Care Practitioner

Guidelines

2004

Version 1

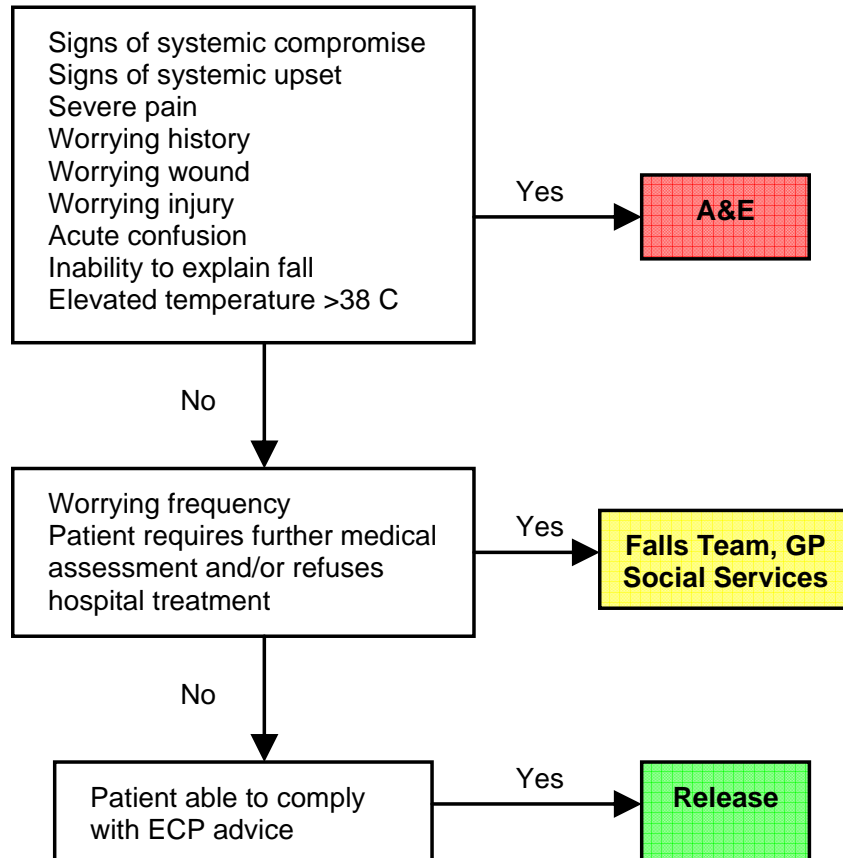
INDEX	
1. Face Page	
2. Index	
Medical	
3. Non traumatic falls	
4. Lower back pain	
5. Cold or flu symptoms	
6. Constipation	
7. Diarrhoea	
8. Paronychia	
9. Post operative wound problem	
10. Blocked urinary catheters	
11. Non traumatic epistaxis	
Trauma	
Lower Limb Injury	
12. Ankle	
13. Ottawa ankle rules	
14. Grades of ankle STI	
15. Knee injury	
16. Calf problems	
17. Pre-tibial laceration	
18. Achilles injury	
Upper Limb Injury	
19. Elbow injury	
20. Pulled elbow (subluxation)	
21. Mallet finger	
22. Wrist injury	
23. Humerus	
24. Clavicle	
25. Gamekeepers thumb	
26. Injured forearm	
	<i>Trauma continued...</i>
	Ophthalmic
	27. Eye Injury (general)
	28. Corneal abrasions
	29. Corneal foreign body
	30. Arc eye
	31. Sub Tarsal foreign body
	32. Chemical eye injuries
	33. Conjunctival foreign body
	ENT
	34. Toothache
	35. Removal of foreign body (ear)
	36. Removal of foreign body(nose)
	Trauma (various)
	37. Minor head injury
	38. Wound care
	39. Ingested foreign body
	40. Bites & stings (insect/fish)
	Burns
	41. Burns
	Psycho/Social
	42. Emotional or hysterical reaction
	43. Psychiatric problems

FALLS (without injury)

Falls

Using this flowchart for any patient that has fallen and the cause of the fall can be explained. If the patient cannot explain the fall or had experienced dizzy spells prior to the fall then the patient should have a full medical assessment including BP and ECG.

Clinical Care Pathway



Advice

Care package in place?
Contact 999 if evidence of deterioration
See relevant advice sheet
If wound present check tetanus status

LOWER BACK PAIN

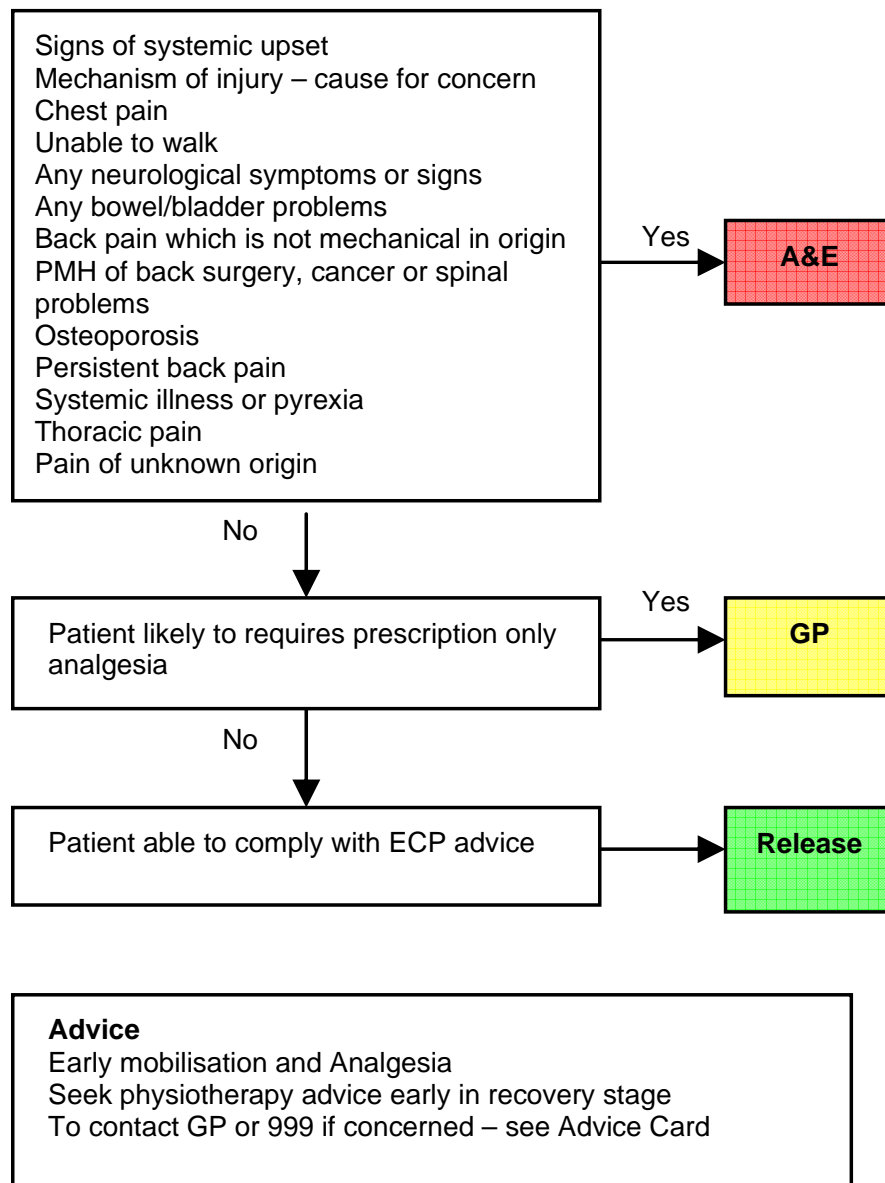
Lower Back Pain

The patient describes a pain isolated to the lower back, which is aggravated by movement which is usually precipitated by lifting or twisting.

While the assessment and management of mechanical back pain is within the scope of the Emergency Care Practitioner, patients suffering back pain from another cause must be assessed by a Doctor.

IF IN DOUBT: REFER

Clinical Care Pathway



COLD OR FLU SYMPTOMS

Cold or flu symptoms

Patients will often complain of pyrexia associated with general muscle pains, headache, runny nose, cough etc.

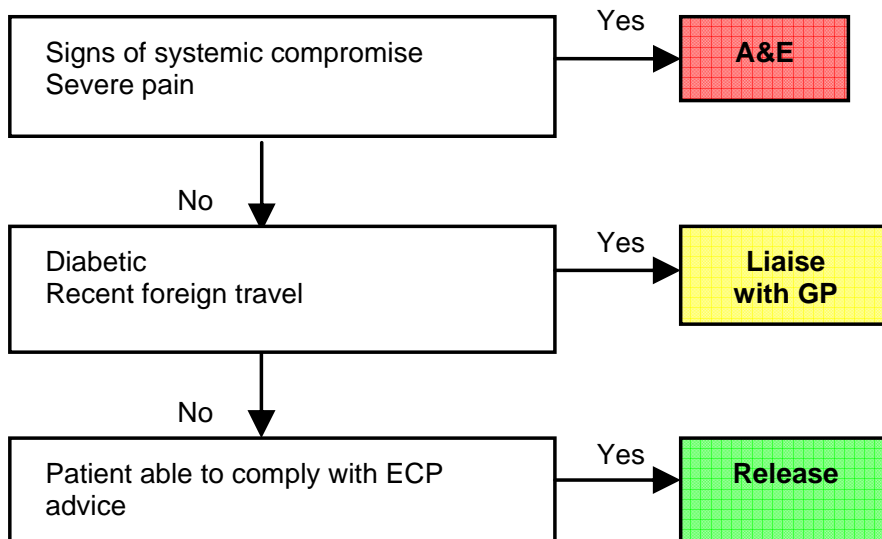
Signs of systemic compromise

Temperature >39 degrees Celsius or fever not responding to Paracetamol
Headache not relieved with simple analgesia
Photophobia
Neck stiffness
Rash

History of foreign travel

Travel to an area where the patient was advised malaria prophylaxis was required.

Clinical Care Pathway



Advice

Take simple painkillers which suit patient, advice patient to see pharmacist to discuss further treatment.
Drink plenty of fluids
See advice sheet

CONSTIPATION

Constipation

The patient complains that they are unable to pass stools for over 48 hours. The patient should have passed wind and should be specifically asked about this.

Signs of systemic upset

Anything during the assessment of the patient that would suggest co-existing acute pathology such as infection.

Check

Temperature
Dehydration
Vomiting
Current and recent medication

Abnormal pain

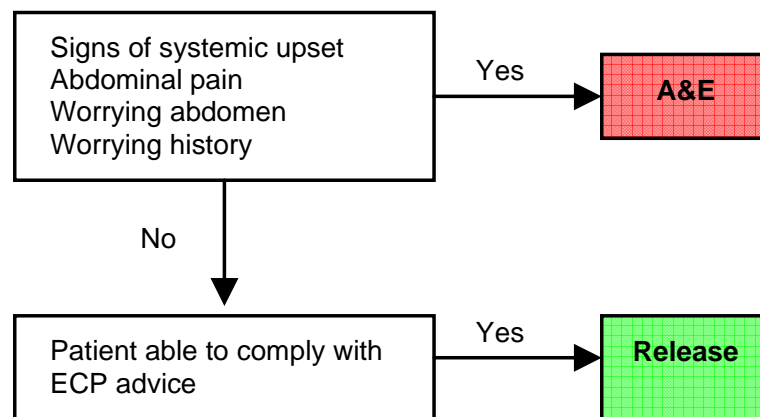
Any pain in the abdomen other than very mild pain

Worrying Abdomen

Any patient who has:

- Not passed wind or motions from the back passage for over 24 hours
- Vomiting
- Abdominal distension
- Previous abdominal surgery

Clinical Care Pathway



Advice

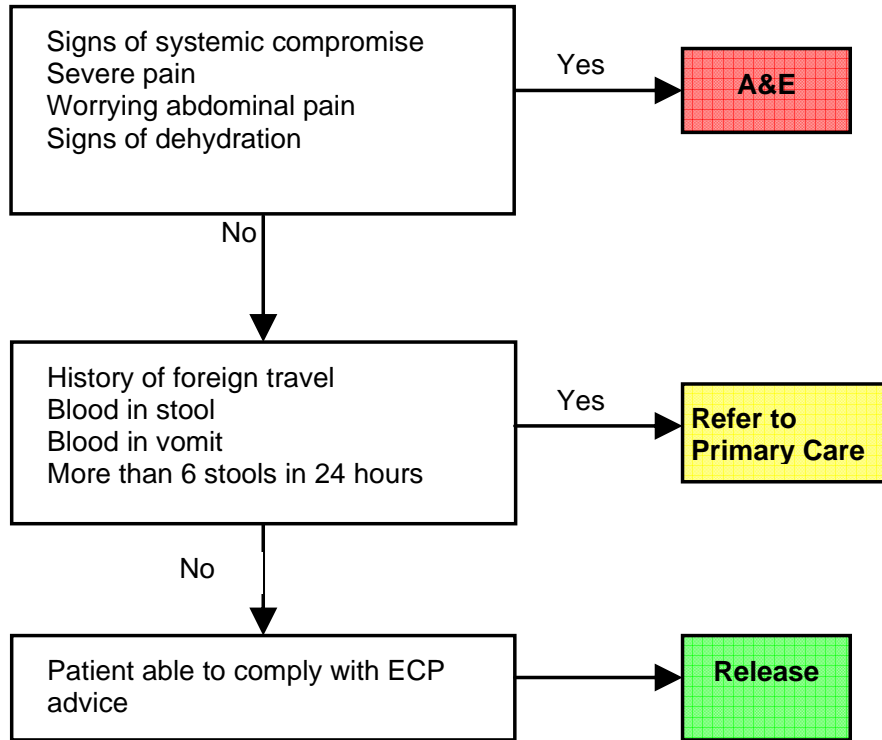
Drink plenty of fluids
See pharmacist to discuss further treatments

DIARRHOEA

Diarrhoea

Patient has diarrhoea or patient has diarrhoea and vomiting.

Clinical Care Pathway



Advice

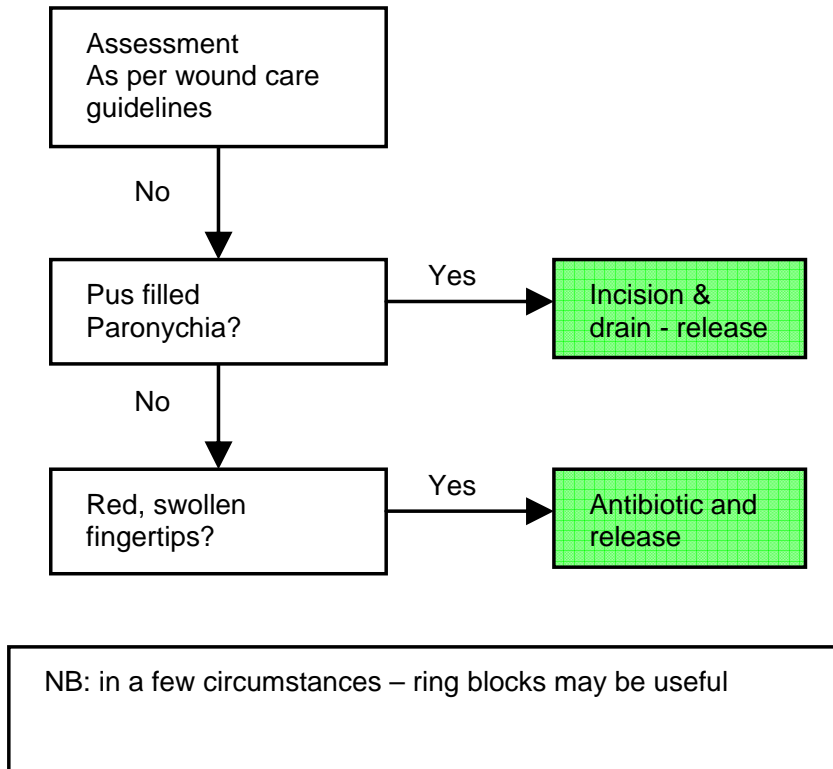
Patient to see pharmacist to discuss available treatments
Drink plenty of fluids
Rest in bed
See advice card

PARONYCHIA

Paronychia

Paronychia is a common hand infection, usually caused by staphylococci. It sets in at the nail fold and causes pus-filled painful swelling and sometimes spreading cellulites. However, recurrent infections may be due to herpes simplex infection (herpetic whitlow) or fungus.

Clinical Care Pathway



POST OPERATIVE WOUND PROBLEM

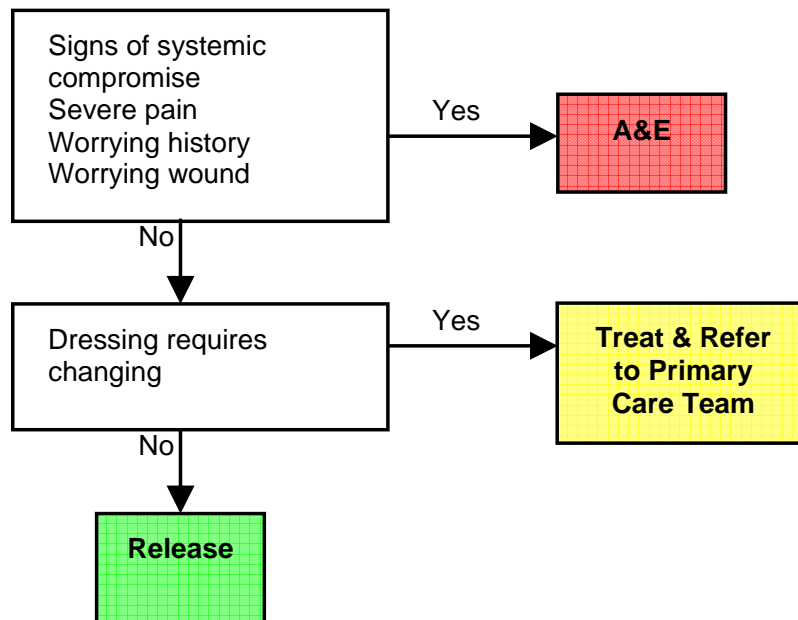
Post Operative Wound Problem

The patient has had a recent operation and now is experiencing problems with the wound.

Cause for concern

- Wound greater than 5cm of surrounding redness
- Feels warm to touch
- Underlying tissue visible
- Smelly discharge
- Heavily contaminated

Clinical Care Pathway

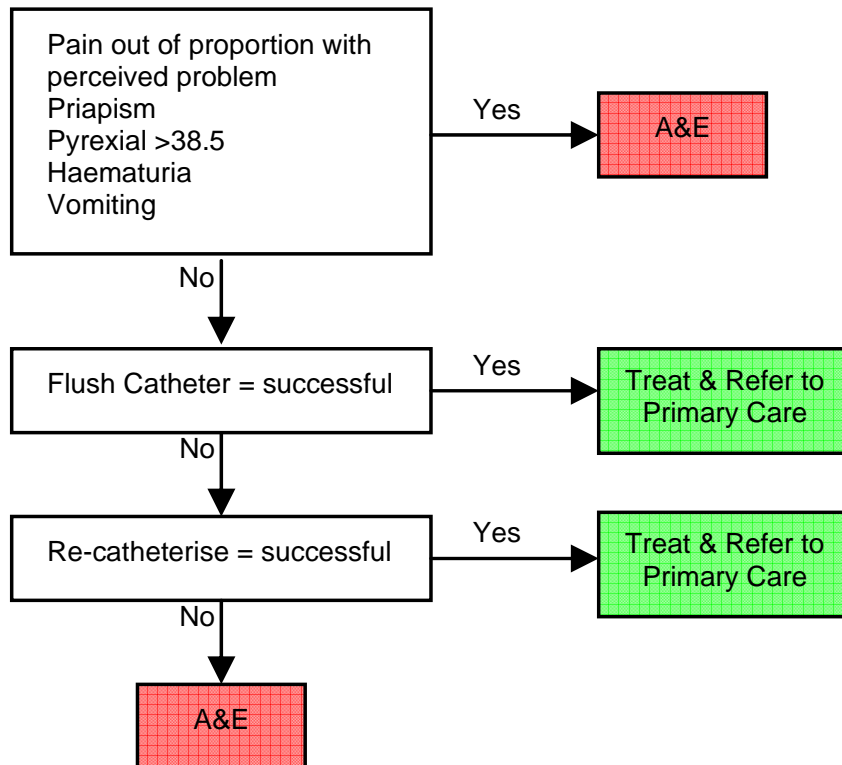


BLOCKED URINARY CATHETER (male)

A urinary catheter may become completely blocked which results in increased abdominal pain associated with no passage of urine when urine would be expected. Urine may also be bypassing the catheter.

Care must be taken to prevent haemodynamic instability resulting from extremely rapid drainage.

Clinical Care Pathway



Advice

If successfully treated...

Drink plenty of fluids

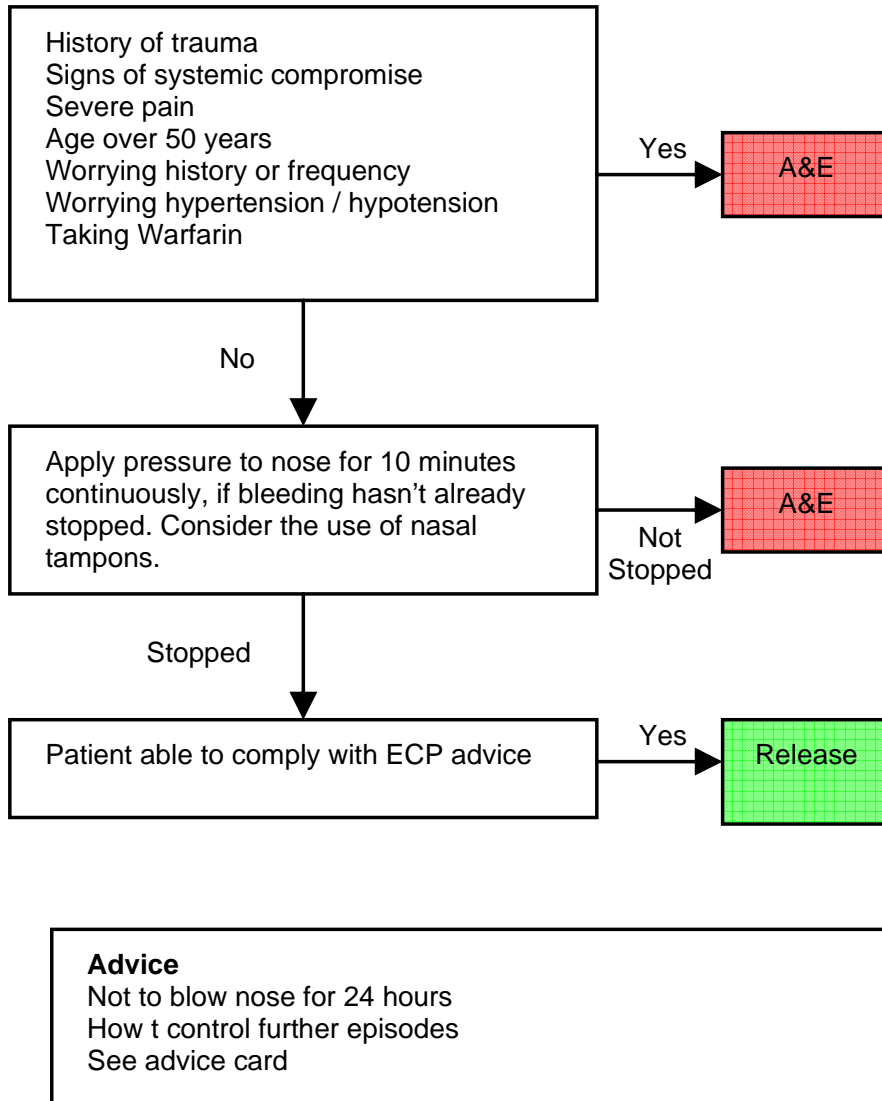
Contact NHS Direct or GP if any concerns post ECP interventions.

NON TRAUMATIC EPISTAXIS

Epistaxis

Bleeding from one or both nostrils as a result of a non traumatic cause

Clinical Care Pathway



ANKLE INJURY

Mechanism of Injury

Inversion = lateral ligament, base of 5th metatarsal.

Eversion = deltoid (medial) ligament, navicular.

Inversion/eversion/forced dorsiflexion = anterior tibiofibular ligament, navicular

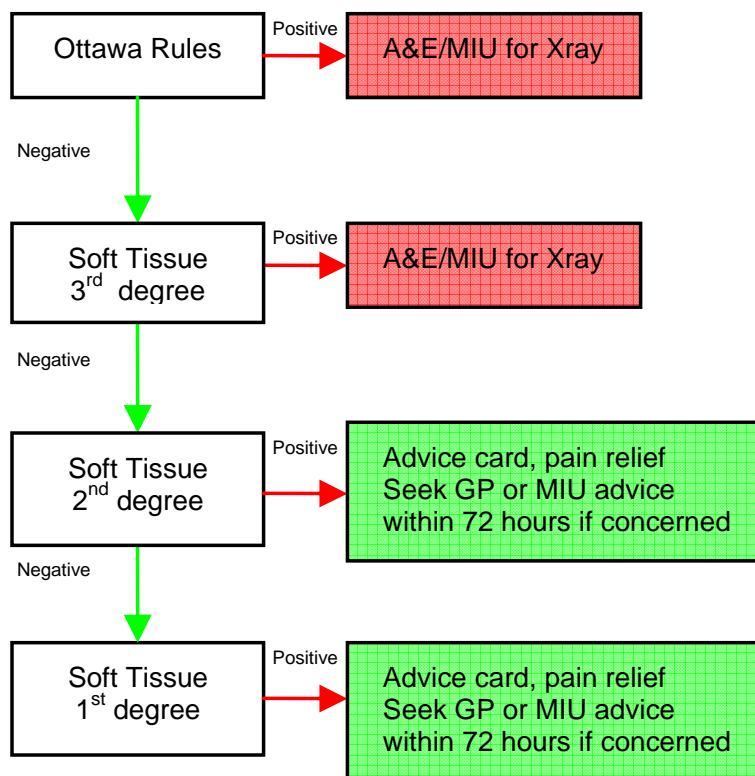
Patients often hear an audible crack, which is the tendon/ligament often mistaken for the sound of “bone breaking”.

Examination

Knee – fibula head – check down tibia and fibula – medial and lateral malleolus – navicular – mid foot – base of 5th metatarsal – calcaneum – toes.

These Guidelines do not apply if <16 years, >55 years, injury >10 days old, impaired sensorium (alcohol/paraplegia/multiple injuries)

Clinical Care Pathway



OTTAWA ANKLE INJURY RULES

Lateral view

(A) Posterior edge or tip of lateral malleolus

6cm

Malleolar zone

Midfoot zone

(C) Bass of fifth metatarsal

Medial view

(B) Posterior edge or tip of medial malleolus

6cm

(D) Navicular

6cm

An ankle radiographic series is only required if there is any pain in the malleolar zone and any of these findings:

- Bone tenderness at A or
- Bone tenderness at B or
- Inability to bear weight both immediately and in A&E

A foot radiographic series is only required if there is any pain in the midfoot zone and any of these findings:

- Bone tenderness at C or
- Bone tenderness at D or
- Inability to bear weight both immediately and in A&E

(Steill et al 1995, by permission of BMJ Publishing Group)

CLASSIFICATION OF ANKLE SOFT TISSUE INJURIES

Evans P. (1980) The healing process at cellular level: a review.

Physiotherapy. 66 (8): 256–259.

A soft tissue injury is an acute connective tissue injury that may involve muscle, ligament, tendon, capsular structures and/or cartilaginous structures. These injuries can be categorised into three grades or degrees of severity of injury.

First degree (mild):

The result of a mild stretch of ligament or capsular structures, or over-stretch or direct blow to muscle. There is minimal swelling and bruising but mild pain is felt at the end of range of movement or on stretch or contraction of muscle. There is no joint instability, minimal muscle spasm and no loss of function.

Second degree (moderate):

The result of moderate stretch of ligament or capsular structures, or excessive stretch or direct blow to muscle, causing tearing of some fibres. There is moderate swelling and bruising, with moderate pain felt on any movement which interferes with the ability of the muscle to contract or lengthen. There may be some joint instability with ligament /capsular injuries. Moderate muscle spasm may result as a reflex response to ligamentous/capsular injuries and muscle injuries. Due to the tearing of some fibres, there is a decrease in the tensile strength of ligament /capsule or a decrease in the contractile strength of muscle, both of which cause interference with function.

Third degree (severe):

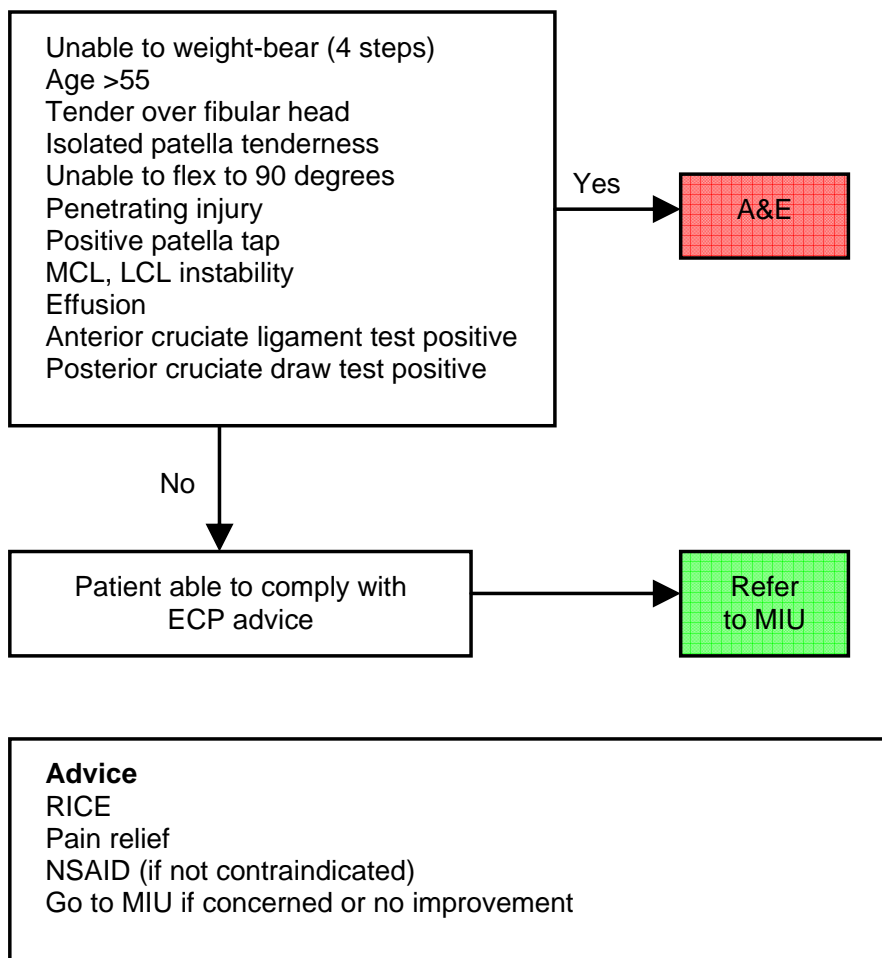
The result of a severe over-stretch of ligament, or excessive stretch or direct blow to muscle, causing a complete tear of the injured structure. There is significant swelling and bruising with severe pain even at rest which significantly interferes with function. Ligament injuries result in gross instability and significant decrease in tensile strength, with muscle injuries causing severe muscle spasm and 'splinting', while the injured muscle is incapable of exerting force. Function is severely impaired.

KNEE INJURIES

Assessment

Early examination in acutely swollen knee is often unreliable.
History – Mechanism of injury, location of pain – Assess motor and sensory function of whole leg, always consider hip and spine problems when assessing a painful knee.

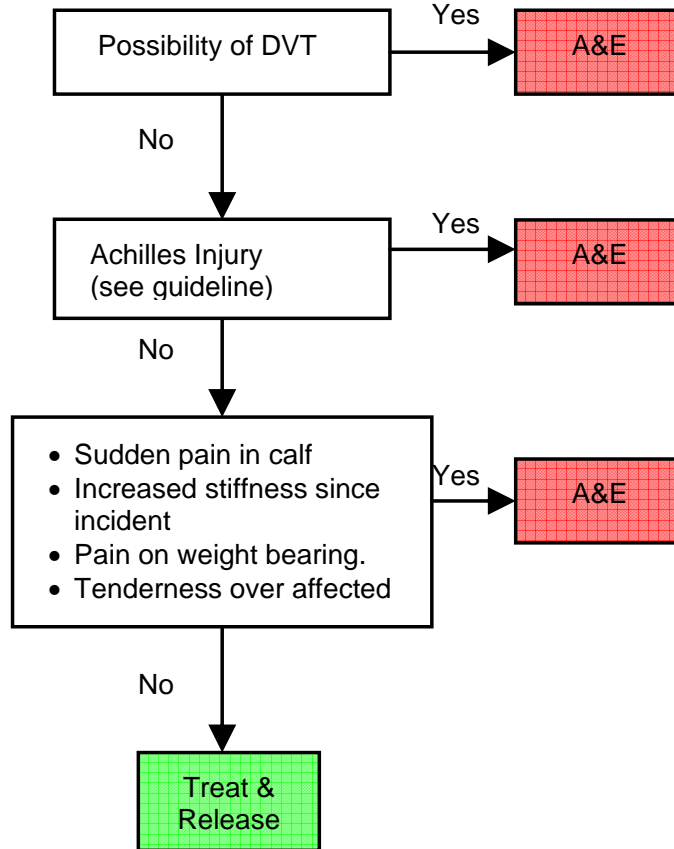
Clinical Care Pathway



CALF PROBLEMS

Acute tears of the calf muscles may occur during sports, alternatively they may occur following relatively minor injuries e.g. stepping from a bus or kerb or following sudden movement.

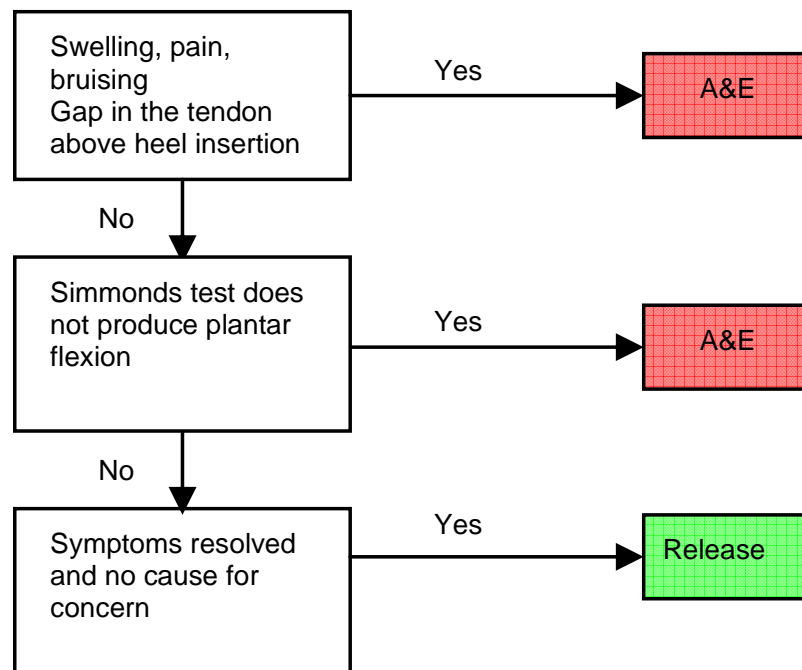
Clinical Care Pathway



ACHILLES TENDON RUPTURE

Rupture of the Achilles tendon typically occurs during sporting activities although it may also occur after falling or performing sudden movements. Patients will often present with a history of very sudden severe pain with or without an audible or palpable bang. This pain is so severe that patients often feel that they have been struck from behind or shot in the back of the leg.

Clinical Care Pathway



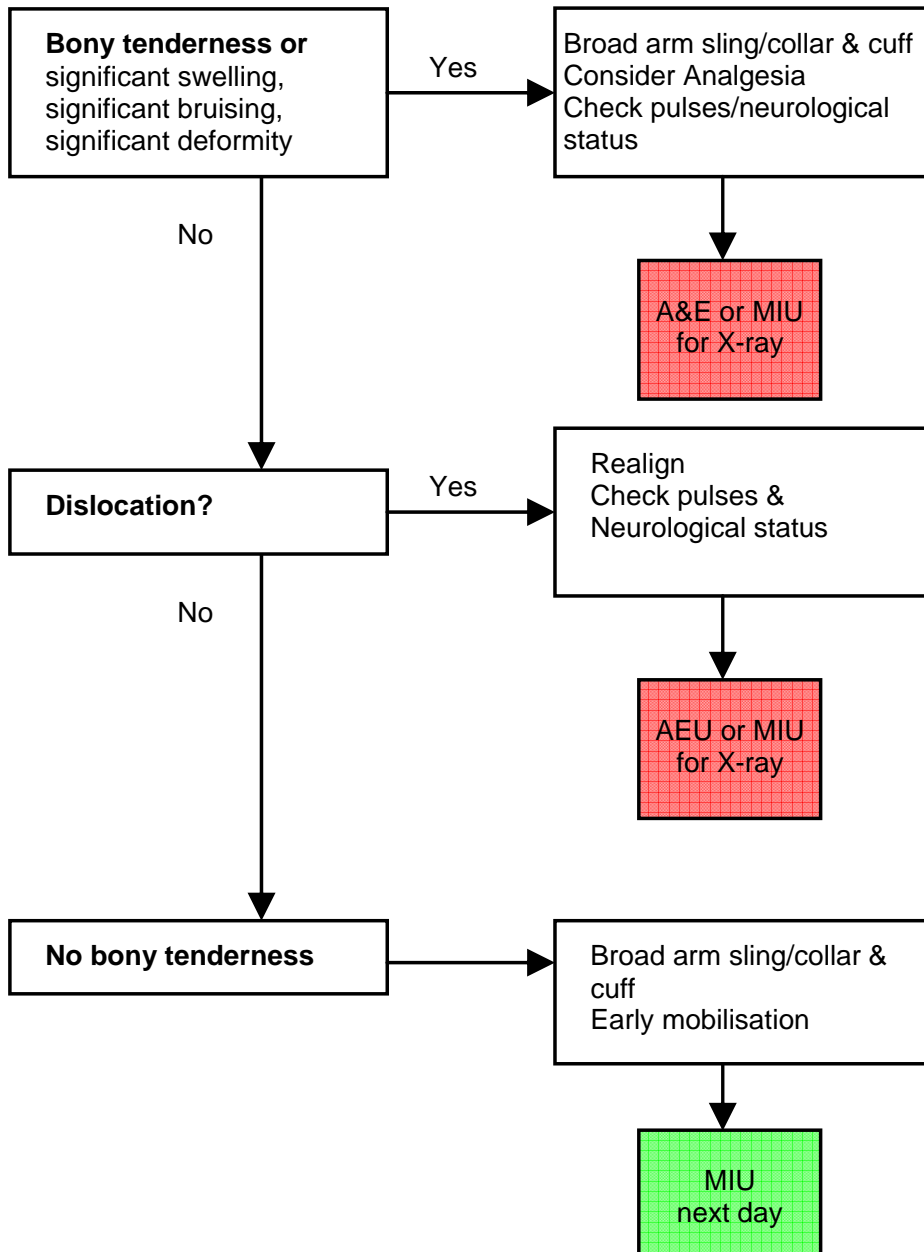
PRE-TIBIAL LACERATIONS

Management

1. Suturing should be avoided.
2. Close with self-adhesive strips and cover with non-adherent dressing.
3. A double layer of elasticised tubular bandage (tubigrip) should be applied, if no contraindications, from toe to knee. The patient must be advised to remove this at night.
1. Advise patient not to stand for long periods, to rest with the limb elevated and to perform regular ankle and leg exercises.
5. A follow-up appointment for redressing at the patient's GP surgery or with the District Nurse should be arranged for 5-7 days.

ELBOW (see also Pulled Elbow)

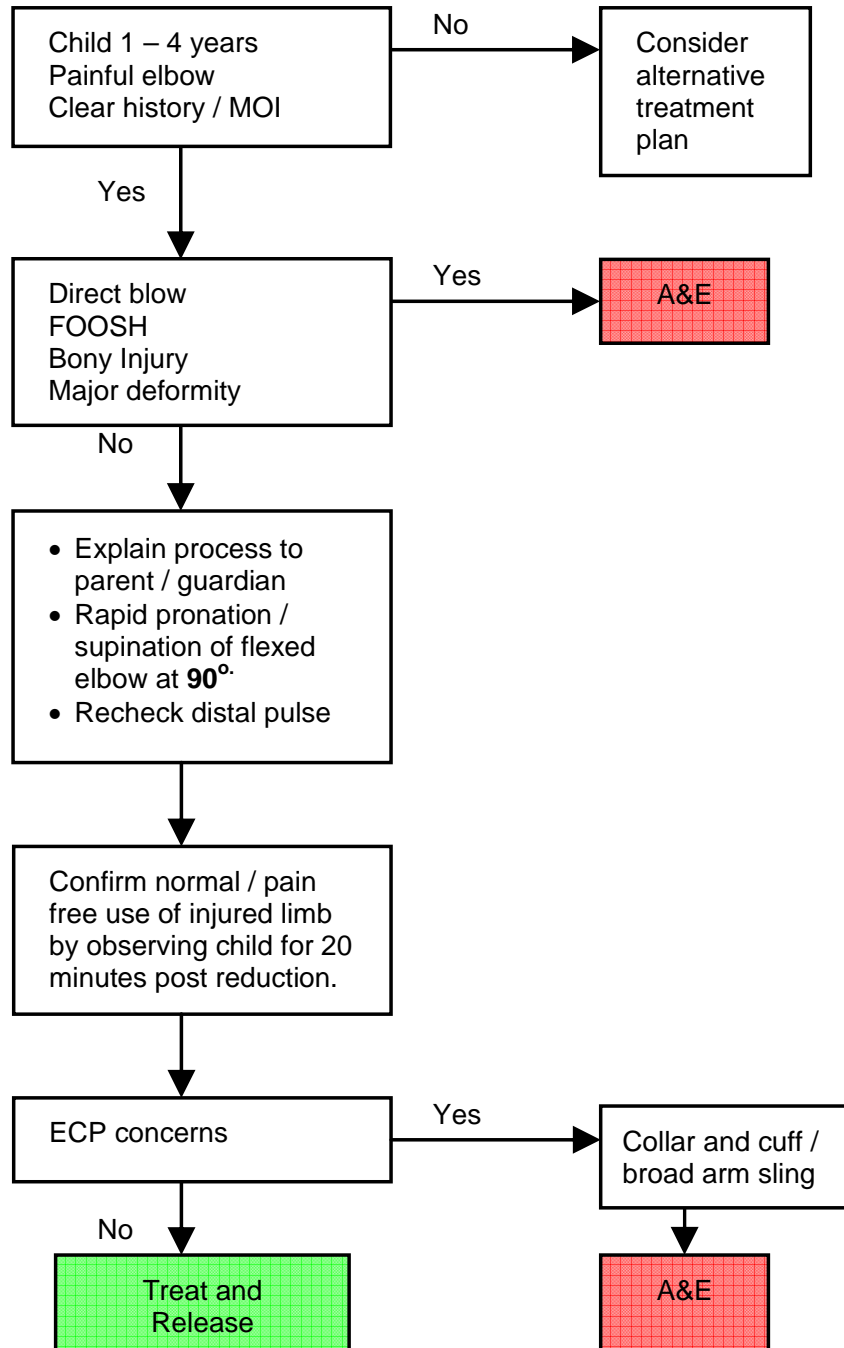
Clinical Care Pathway



PULLED ELBOW (Subluxation of Radial Head)

The Emergency Care Practitioner can treat and release a patient with a pulled elbow provided that there is a clear history (MOI) of traction injury and the elbow is reduced at first attempt.

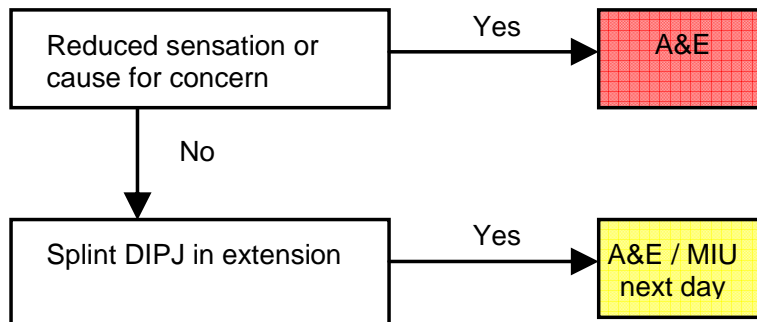
Clinical Care Pathway



MALLET FINGER

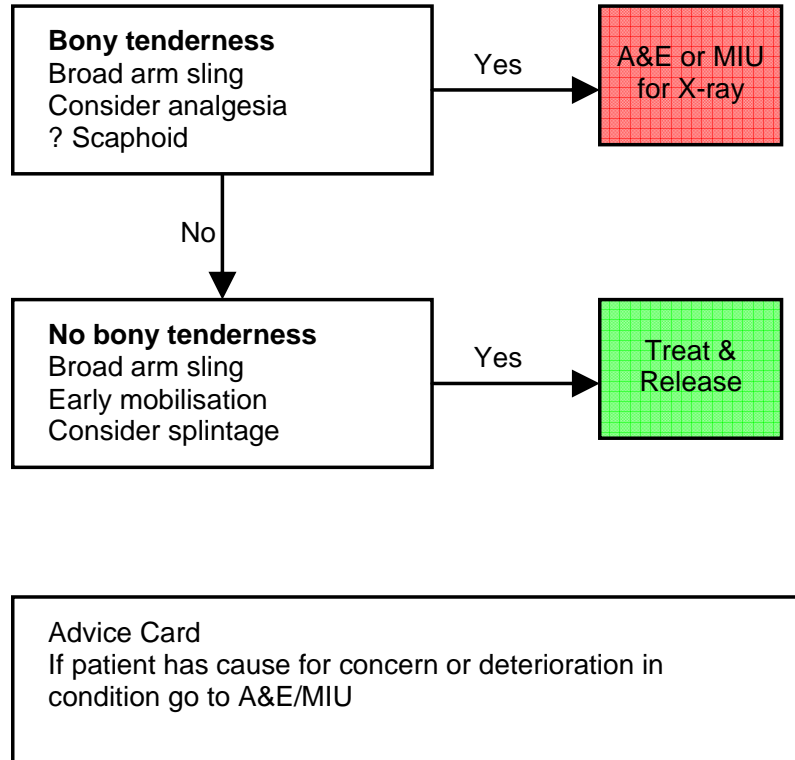
A forced flexion at the DIP joint as a result of a fall or direct blow may result in injury to the extensor mechanism distal to the interphalangeal joint.

Clinical Care Pathway



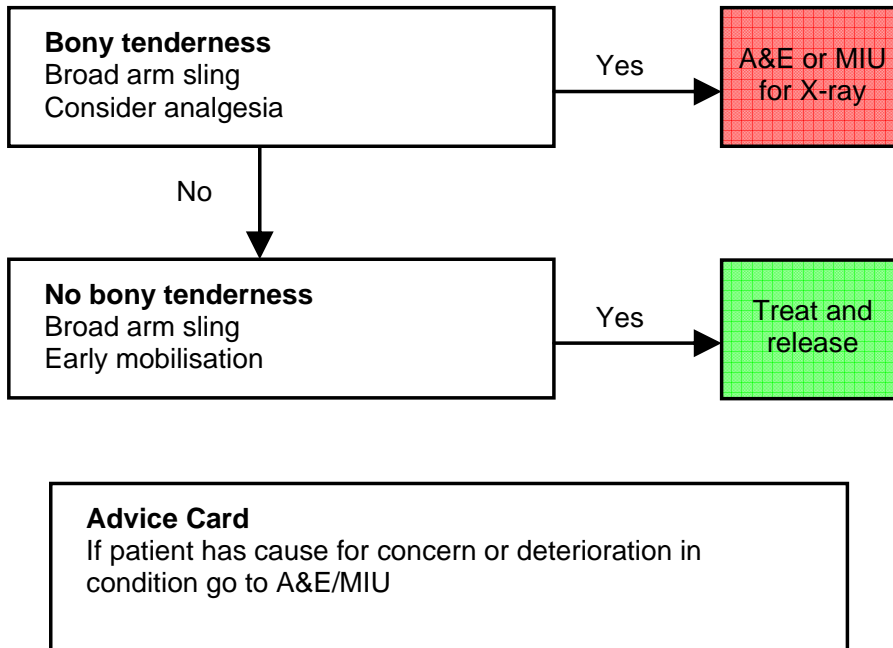
WRIST

Clinical Care Pathway



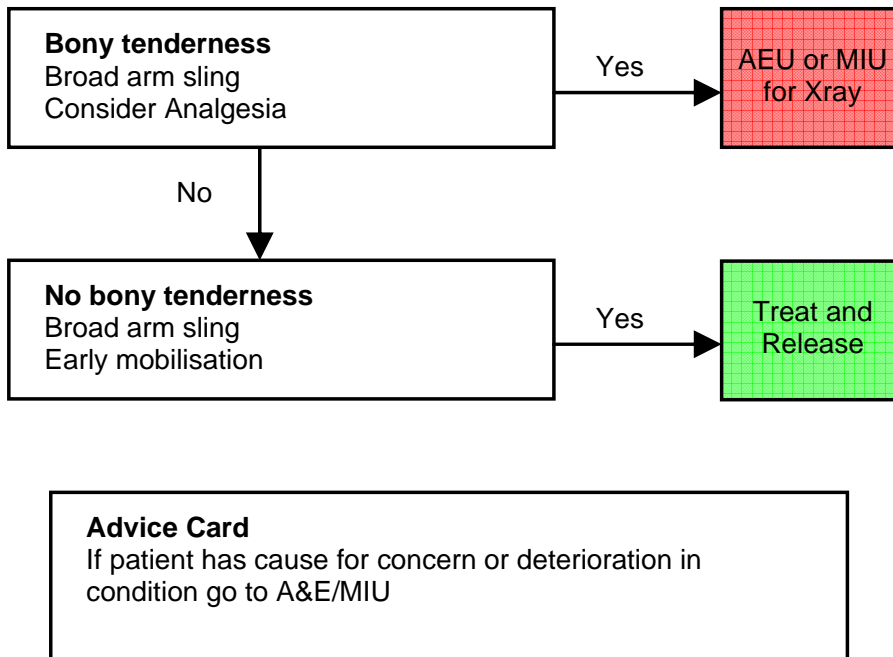
HUMERUS

Clinical Care Pathway



CLAVICLE

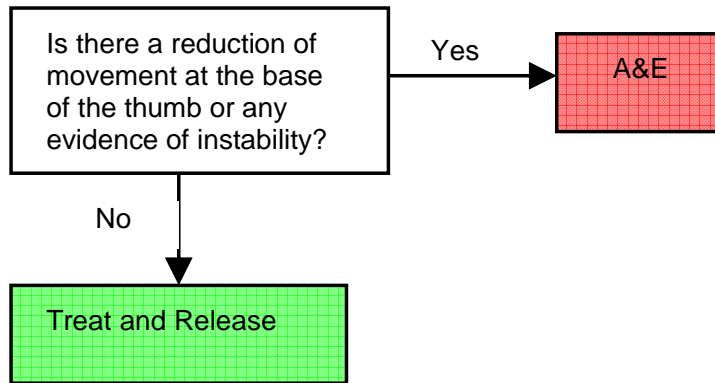
Clinical Care Pathway



GAMEKEEPERS THUMB

Gamekeepers thumb is the rupture of the ulnar collateral ligament of the thumb metacarpophalangeal joint. There is the potential for long term reduction in the 'pinch grip' if diagnosis and treatment is not dealt with as a matter of urgency.

Clinical Care Pathway

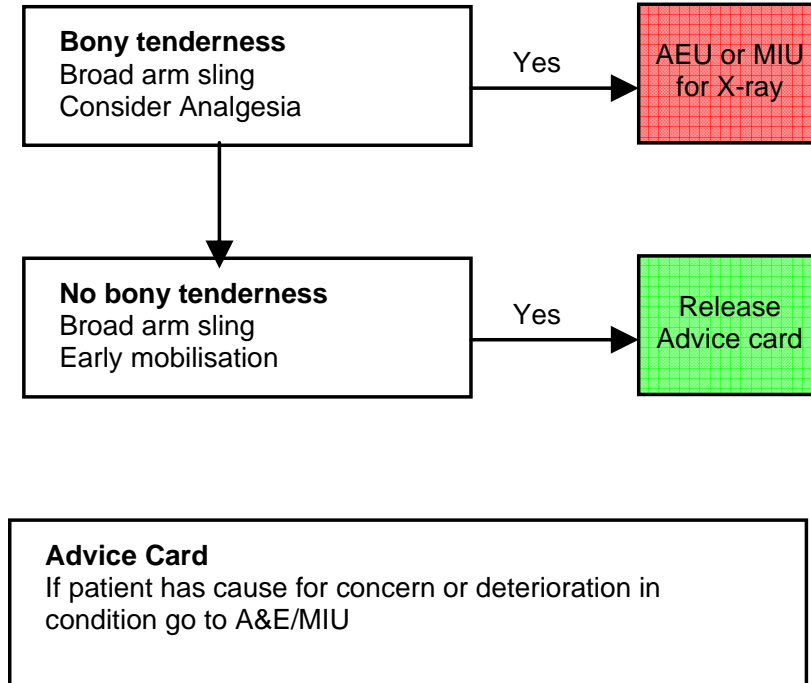


Advice Card

If patient has cause for concern or deterioration in condition go to A&E/MIU

FOREARM

Clinical Care Pathway



EYE INJURIES (general)

Eye injuries

The following are suitable injuries for ECP assessment:

Corneal foreign body

Corneal Abrasions

Arc eye

Assessment

Exact mechanism of injury

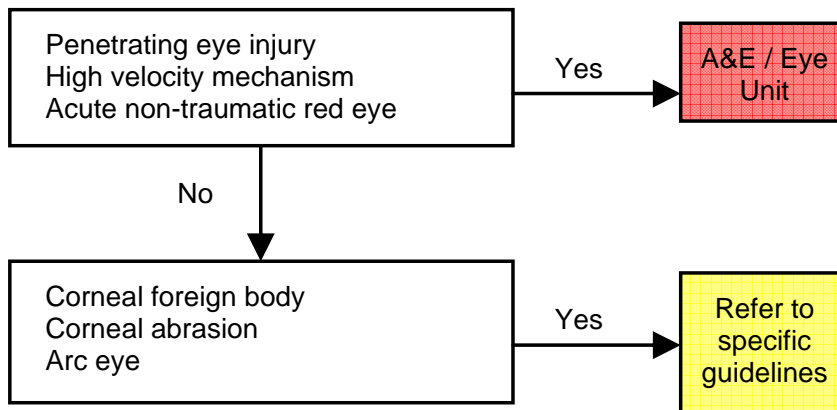
Visual acuity test recorded

Current symptoms

Refer to specific guidelines

Below is a basic flowchart for clinical care pathway for eye injuries. See also specific eye injury pathways in the next few pages.

Clinical Care Pathway



CORNEAL ABRASION

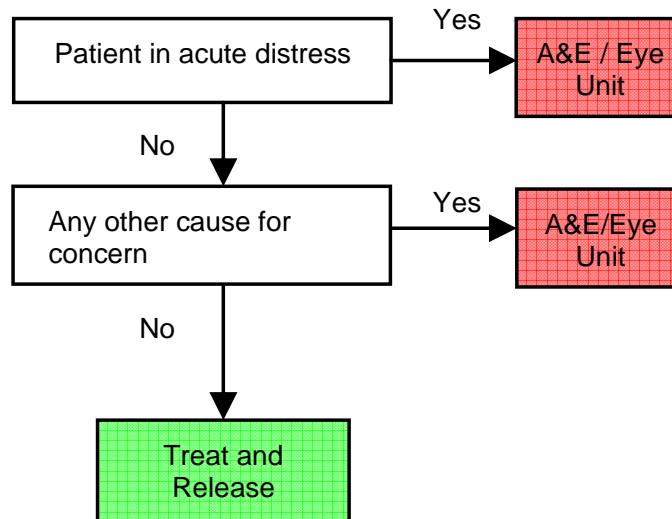
This often occurs as a result of a scratching to the eye such as a fingernail, paper or most commonly a foreign body. Patient often complains of irritation therefore early administration of local anaesthesia is advised.

Corneal abrasion is normally diagnosed following;
Local anaesthesia
Fluorescein administration.
If a Foreign body is in situ refer to FB guidelines.

Assessment

See general guidelines

Clinical Care Pathway



Advice

Do not use machinery or drive for 20 minutes per drop of local anaesthetic used.

If condition no better after 24 hours to attend MIU/A&E

Advice cards on eye drops, eye patches, and corneal abrasion. When anaesthesia wears off pain may return – take simple analgesia

Administer Fucithalamic ointment and give to patient as TTA.

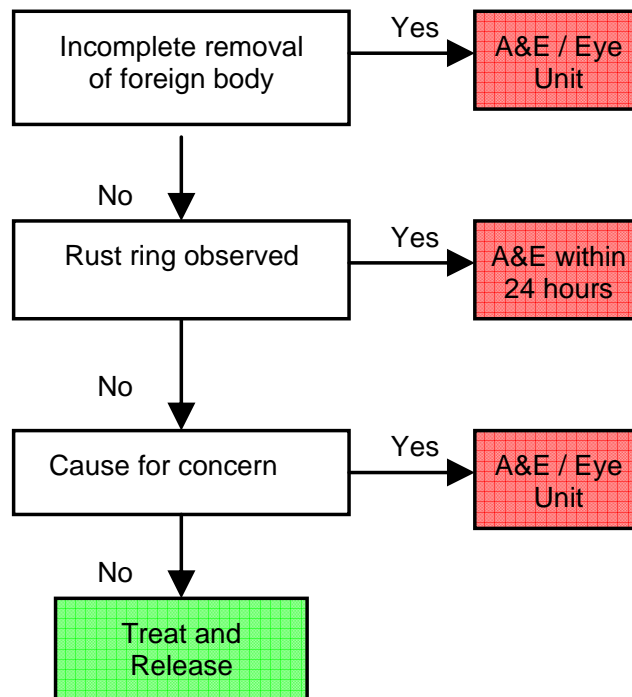
CORNEAL FOREIGN BODY

Clinical Care Pathway

Management

Local anaesthetic
Removal of foreign body with cotton bud
Check for corneal abrasion (see 'corneal abrasion')

Clinical Care Pathway



Advice

Do not use machinery or drive for 20 minutes per drop of local anaesthetic used. If amethecaine wait 2 hours.
If condition no better after 24 hours to attend MIU/A&E
Advice cards on eye drops, eye patches and corneal abrasion

ARC (welder's) EYE "snowblindness"

Exposure to ultraviolet light can cause superficial keratitis. Climbers/skiers, welders, and those under sunbeds who have not used protective goggles develop pain, watering, and blepharospasm several hours later.

Management.

1. Local anaesthetic drops to allow examination.
2. Fluorescein staining may reveal multiple punctate corneal lesions.
3. Do not discharge with local anaesthetic drops.
4. Advise patient that anaesthetic drops last for at least 20 minutes (or more, depending on the pigmentation of the eye).
5. Discharge with eye pad, if required, and oral analgesia.
6. Offer patient Health Education advice i.e. eye protection.

SUB-TARSAL FOREIGN BODY

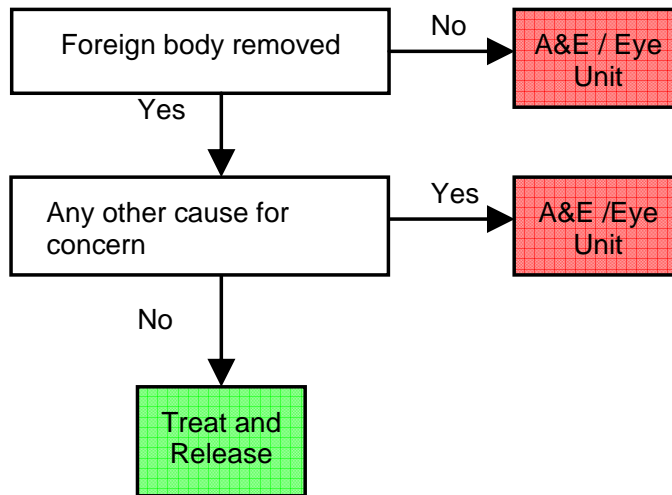
If the foreign body cannot be found in the lower fornix the other most common place to find it is in the stuck under the upper eyelid. The patient will often report of pain on blinking.

Clinical Care Pathway

Management

Local anaesthesia
White light inspection
Sub tarsal
Remove FB with cotton bud
Check for corneal abrasion (see 'corneal abrasion')

Clinical Care Pathway



Advice

Do not use machinery or drive for 20 minutes per drop of local anaesthetic used. If Amethecaine wait 2 hours.
If condition no better after 24 hours attend MIU/A&E

CHEMICAL EYE BURNS

Assessment and Management.

1. Treat all burns with immediate irrigation of the eye with lukewarm normal saline for at least 20 mins, or until the pH of tears has returned to normal 7.4 (a 1L bag of 0.9% saline with standard IV tubing is ideal).
2. Remove particulate foreign material with a cotton bud.
3. Identify the substance involved and contact Poisons Unit.
4. Refer all chemical burns to the nearest A&E/DGH or Eye Hospital as appropriate.

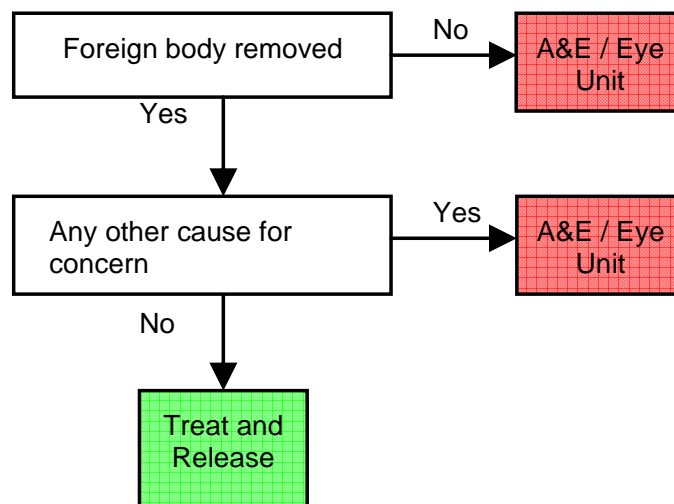
CONJUNCTIVAL FOREIGN BODY

The typical history is dust or grit blown into eye by wind. The foreign body usually gravitates into lower fornix.

Clinical Care Pathway

Management

Local anaesthesia
Sub-tarsal inspection
White light inspection
Remove FB with cotton wool swab from conjunctiva
Check for corneal abrasion (see 'corneal abrasion')



Advice

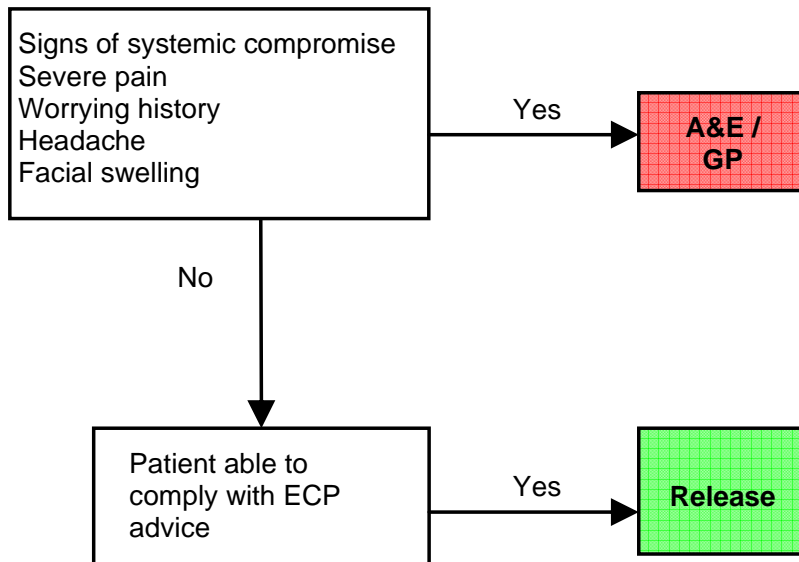
Do not use machinery or drive for 20 minutes per drop of local anaesthetic used. If Amethecaine wait 2 hours
If condition no better after 24 hours, attend MIU/A&E

TOOTHACHE

Toothache

Pain and tenderness located only in a well localised area of the jaw.

Clinical Care Pathway



Dental Review

All patients should be advised to contact their dentist the next day for further advice. If the symptoms are severe then contact emergency dentist. Contact dental help line if available.

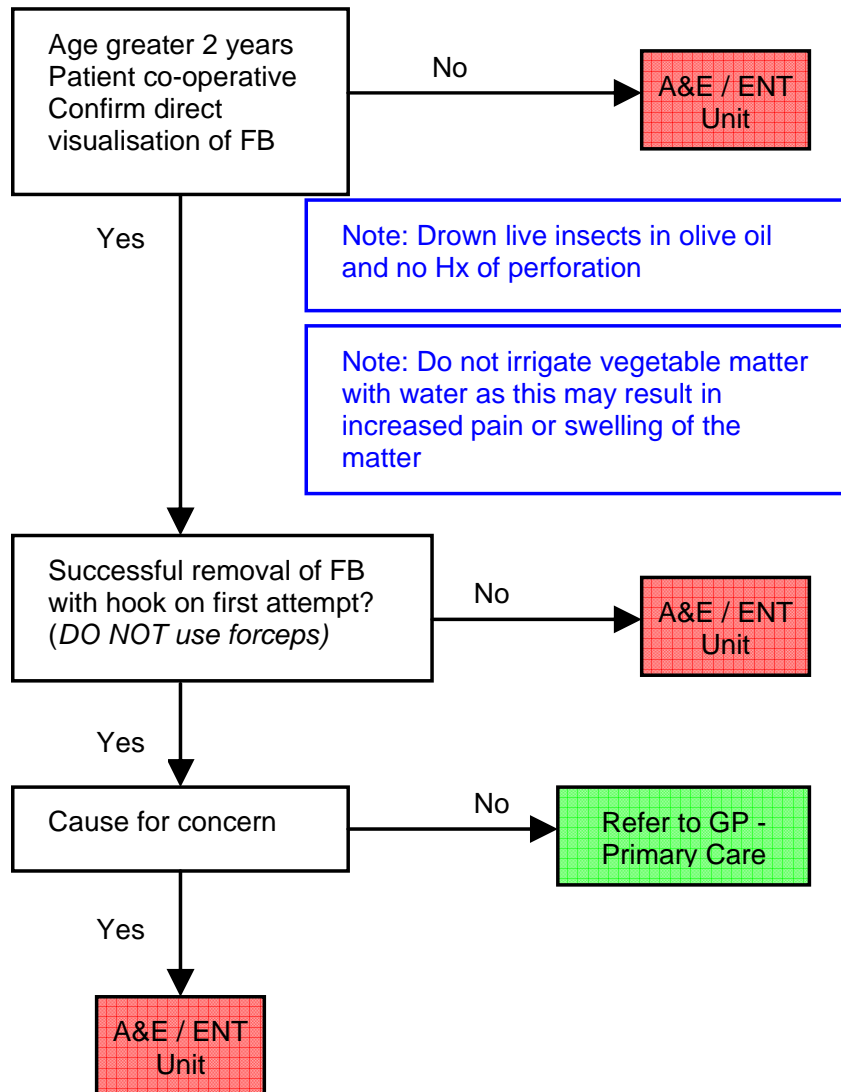
Advice

To see pharmacist to discuss further treatments
To suggest analgesics the patient is able to take
Contact dentist as soon as possible
See advice card

REMOVAL OF FOREIGN BODIES IN THE EAR

All sorts of foreign bodies (FBs) may become lodged in the external auditory canal, including insects, vegetable matter, and various inert objects. The patient may present with pain, deafness, discharge, or in the case of live insects, an irritating buzzing in one ear.

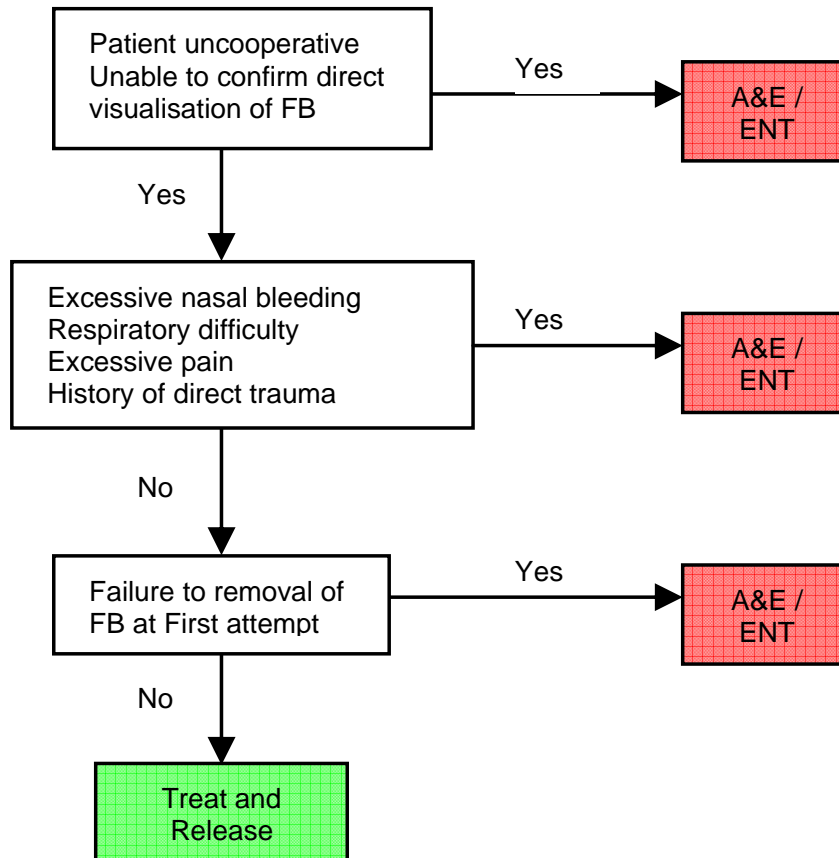
Clinical Care Pathway



REMOVAL OF FOREIGN BODY IN THE NOSE

Note: In children undiagnosed FB in the nose commonly presents as unexplained unilateral rhinitis.

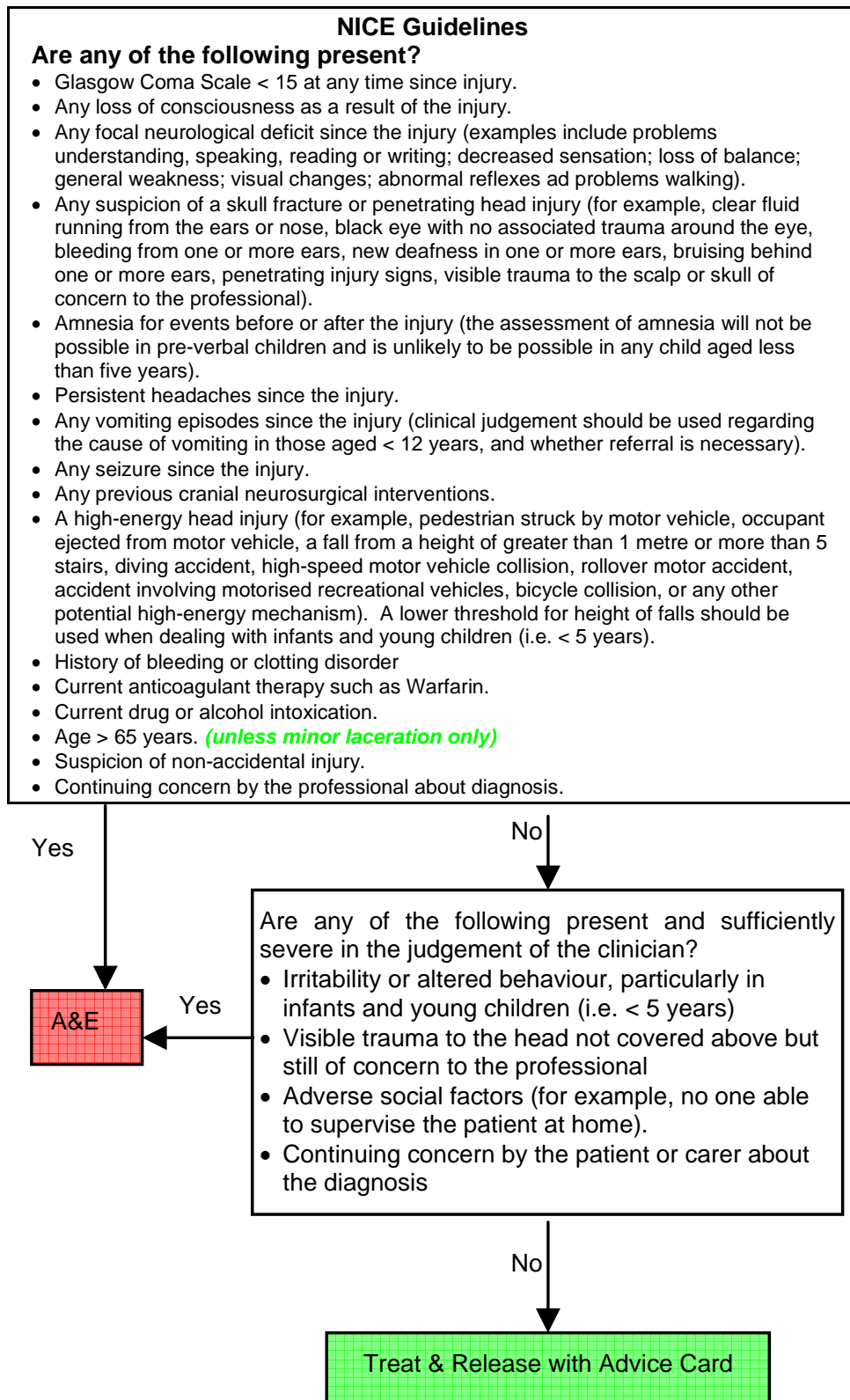
Clinical Care Pathway



- The patient should be positioned in a clear, bright light
- The foreign body should be removed using a Thudicums Speculum and a right-angled probe.
- The foreign body should be carefully inspected to make sure that it is intact (If not intact liaise with ENT Department).
- Document all findings.
- The examination and removal of a foreign body should be documented.
- The patient should be given written discharge instructions and health education advice.

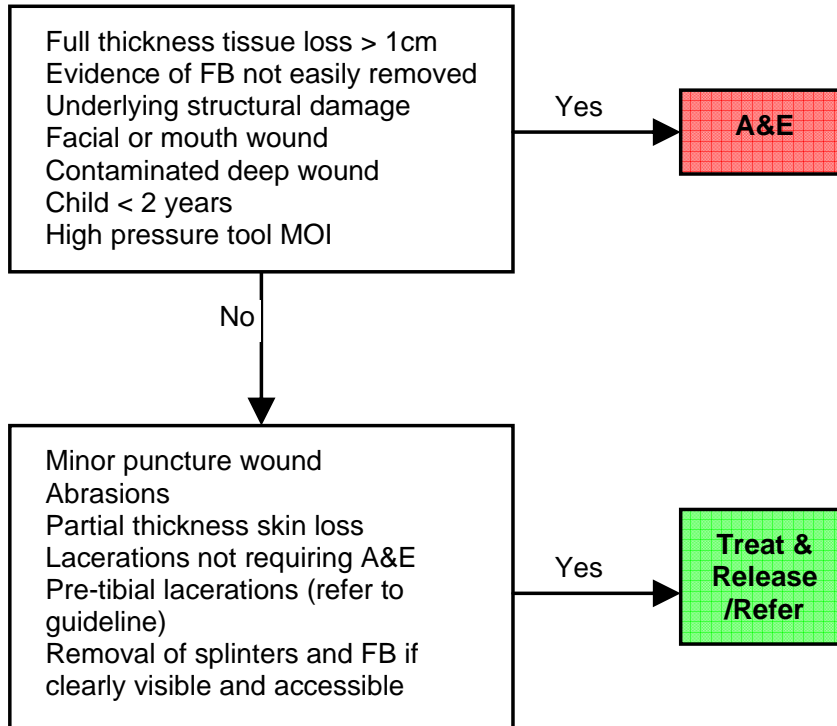
MINOR HEAD INJURIES

Clinical Care Pathway



WOUNDS

Clinical Care Pathway



Type of Wound Closure

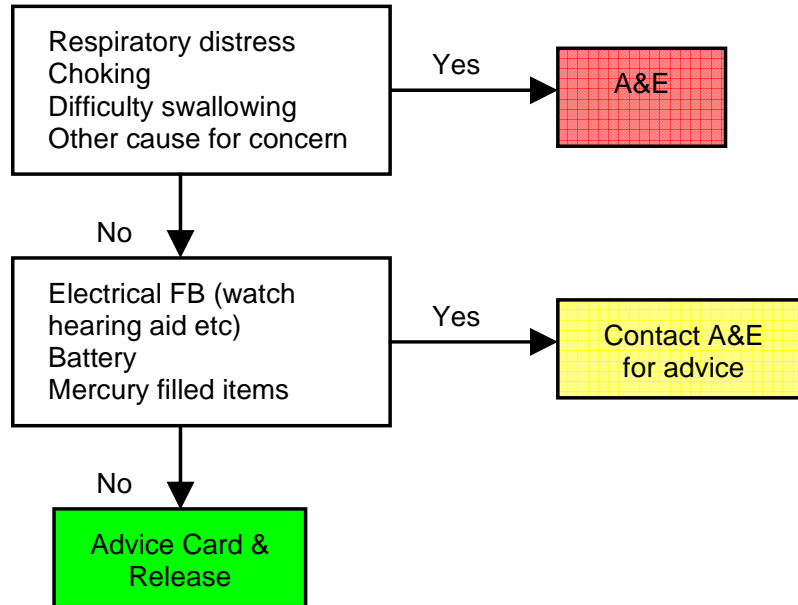
This is a clinical decision which should be made by the ECP and will depend on the competency of the ECP and the anatomical site and type of wound. Options at this time are:

- *Wound closure strips*
- *Tissue adhesive*
- *Sutures*

INGESTED FOREIGN BODIES

A wide variety of foreign bodies both radio-opaque, e.g. coins, rings, batteries and non radio-opaque e.g. plastic pen tops, Lego bricks etc, are frequently swallowed by patients most commonly children or adults with psychiatric disorders. Provided that the foreign body reaches the stomach it is likely to pass through the remainder of the gastrointestinal tract without incident. A common exception is button battery ingestion.

Clinical Care Pathway



Advice

Patients who are completely asymptomatic require no specific follow-up but should be advised to return if they develop any symptoms. Unless the swallowed item is of value or sentimental worth (jewellery, rings etc) then there is no indication to search the stools to prove that the foreign body has passed.

INSECT BITES AND STINGS

Insect Bite or Stings

Usually simple, but occasional multiple areas of insect bite or sting resulting in surrounding redness to the skin.

Generalised rash or swelling

Any rash or swelling which involves more than one limb or a limb and the trunk. The rash will generally be itchy.

Facial or intraoral swelling

Any swelling from the neck upwards?

Visualisation of the mouth is important.

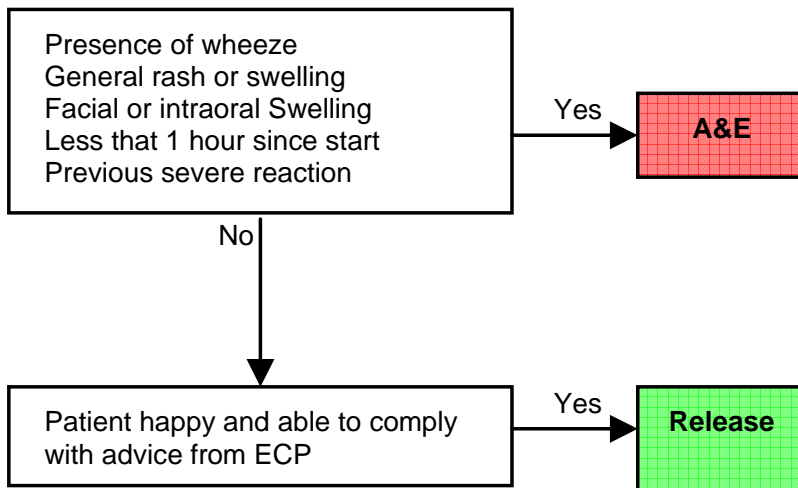
Less than 1 hour since start.

Where speed of onset suggests a more serious condition.

Previous severe reaction

Any previous allergic reactions which required hospital based treatment more than oral antihistamines.

Clinical Care Pathway



Advice

Apply ice pack or frozen vegetables

Rest with effected limb elevated as for swollen injury

Take a simple painkiller which suits patient

Antihistamine which may be obtained from the chemist

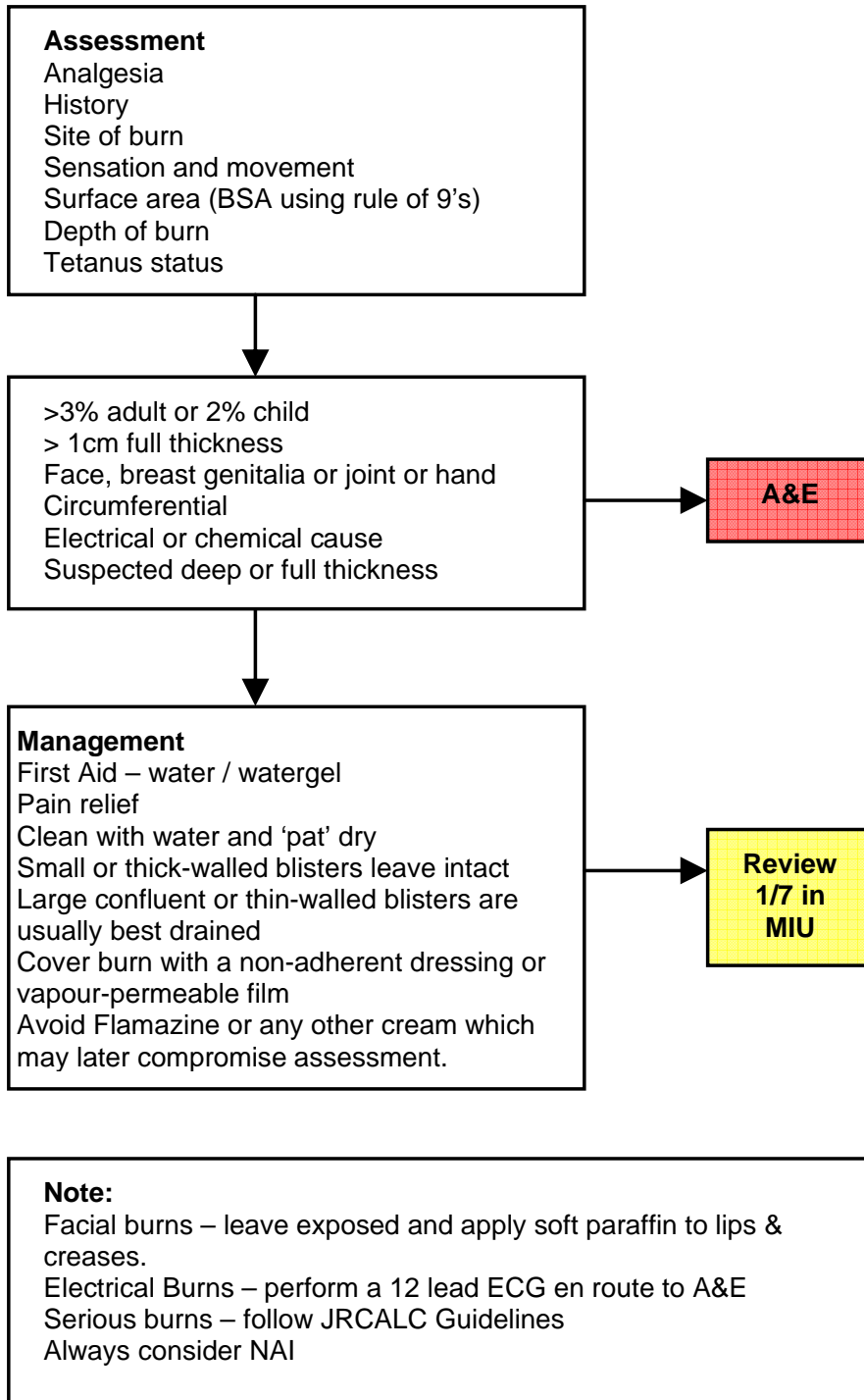
BURNS

Burns

The ECP may treat superficial or partial thickness burns.

Mertens, D.M., Jenkins, M.E., and Warden, G.D. (1997) Outpatient burns management. *Nursing Clinics of North America* 32, 343-364
<http://www.prodigy.nhs.uk/Clinical%20Guidance/ReleasedGuidance/crs/burns.htm#3>

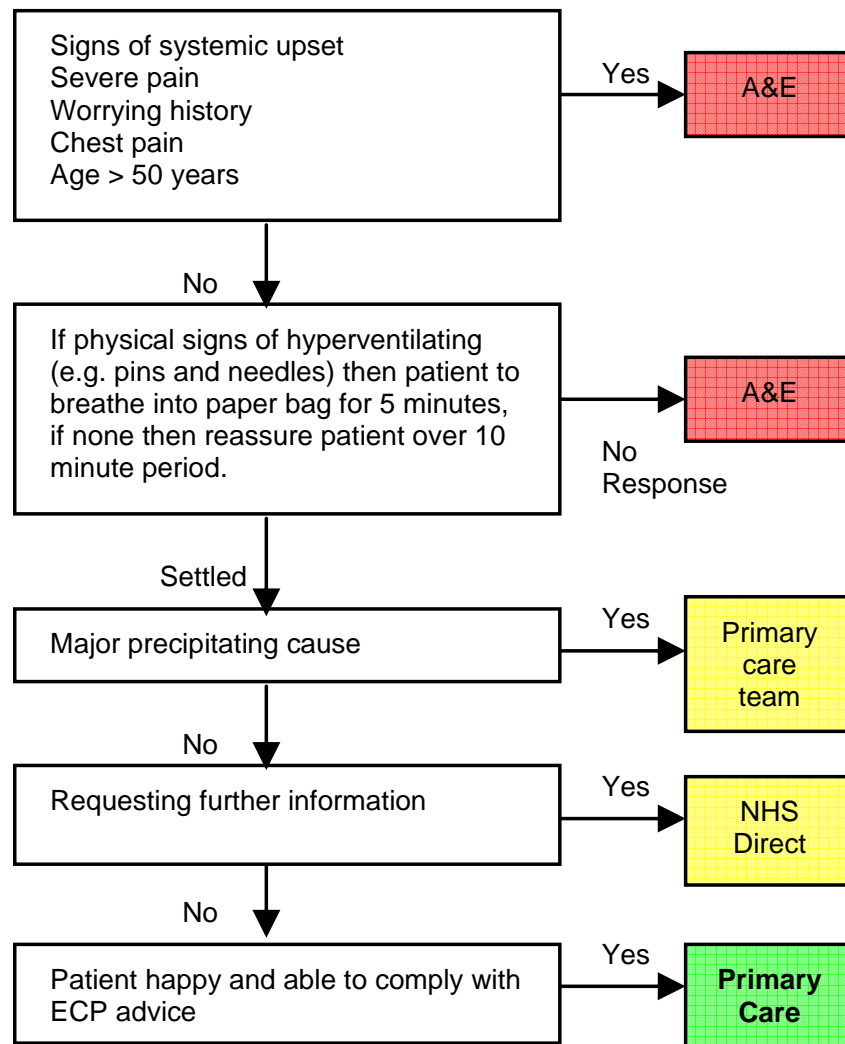
Clinical Care Pathway



EMOTIONAL OR HYSTERICAL REACTION

The patient becomes upset or panicky in response to mild stimulus. The patient will often be hyperventilating with a feeling of being able to take full inspiration of air. The patient may complain of tingling or stiffness to the fingers.

Clinical Care Pathway



Advice

Stay with carer
Patients who continue to have symptoms should contact their GP
surgery or NHS direct for advice
See advice sheet

PSYCHIATRIC PROBLEMS

A medical practitioner or specialist in psychiatry must appropriately assess any patient presenting with an apparent or potential psychiatric problem.

Clinical Care Pathway

